

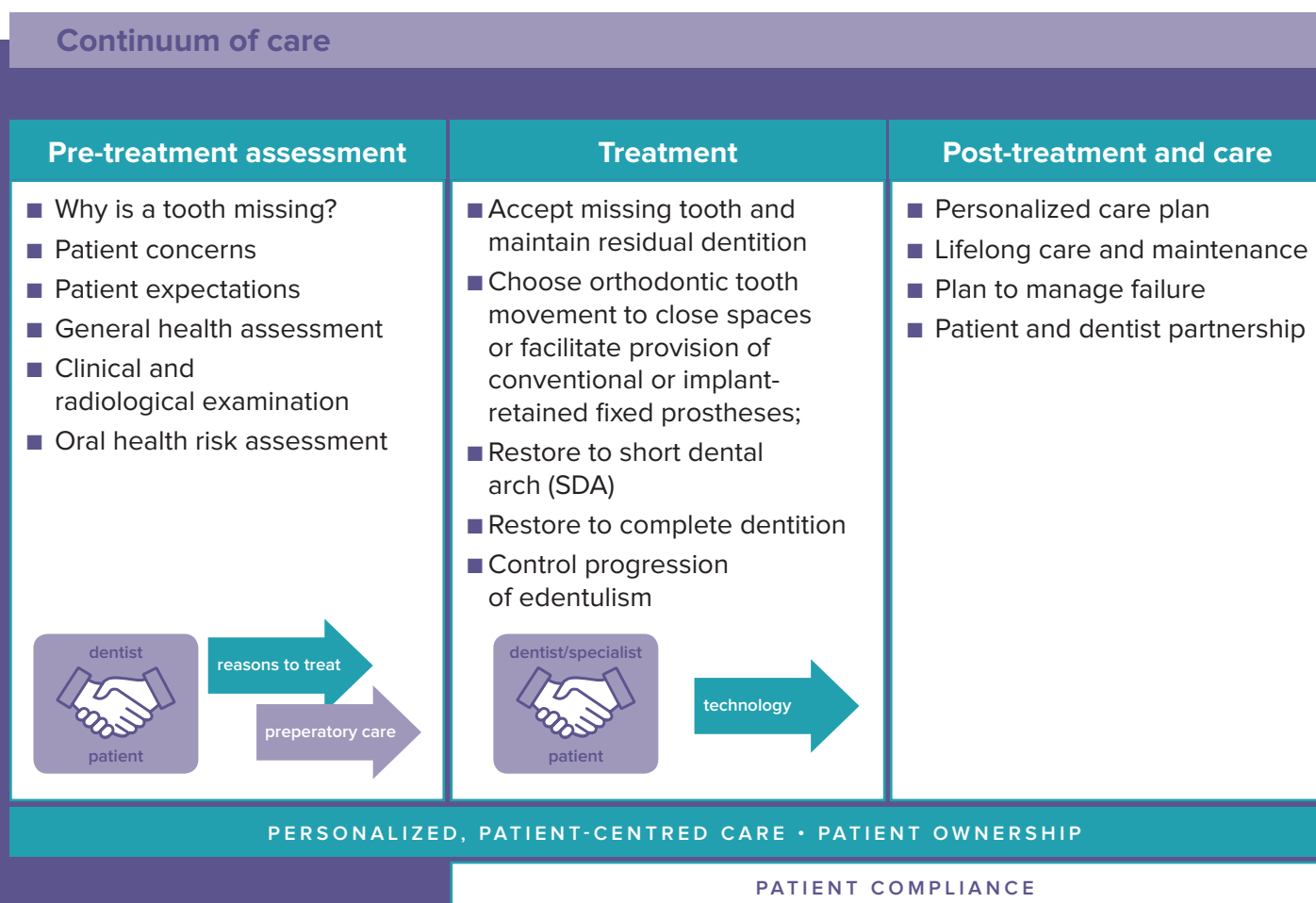


Collaborative Care Continuum: Professional guidelines

A partially dentate patient is someone who has an incomplete natural dentition. One or more teeth are congenitally absent or have been extracted due to disease, trauma, or surgery. This definition applies to different age groups.

Continuum of care

As a dentist, you understand that caring for a partially dentate patient is a longitudinal process that extends over a long period of time and includes three main pillars: a pre-treatment assessment phase, a treatment phase, and a post-treatment and long-term care phase. This guide is here to help you consider each of these three pillars as equally important and to organize your patients' treatment and care plan along this continuum.



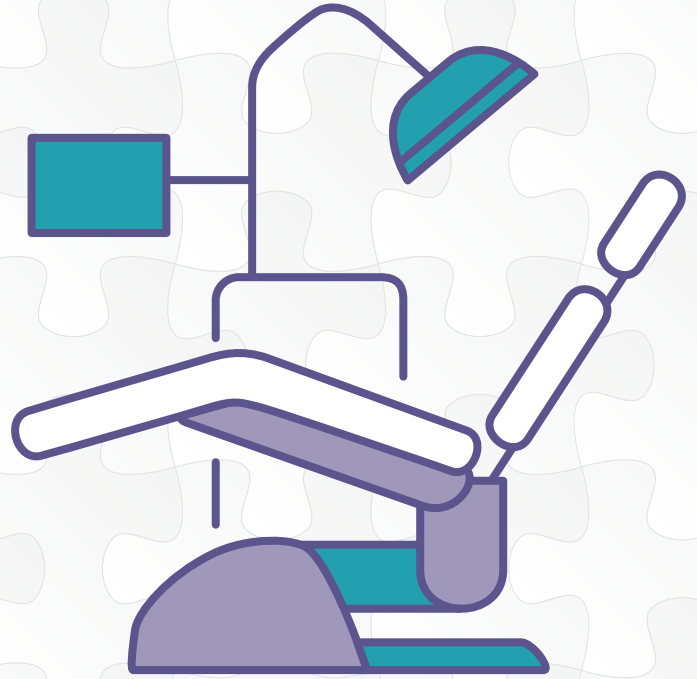The next pages provide you with key elements to help you organize your patients' continuum of care.

Preparatory Care

As a dentist, I am responsible for leading and coordinating the definitive care and the long-term care and maintenance of my patient. I understand that the treatment and care of a partially dentate patient does not fit into a one-size-fits-all model.

The best treatment option, as well as the most adequate supporting technology, depend on the personal situation of each patient. Therefore, I will find the right balance between purely clinical elements and my patient's needs, concerns and expectations.

The checklist below will help you consider all these aspects before coordinating your patient's best care plan.



Checklist before implementing the definitive care plan:

- Identify the personal situation of your patient:
 - ▶ patient's oral/periodontal health status;
 - ▶ patient's oral disease risk;
 - ▶ patient's motivation and participation;
 - ▶ patient's willingness to undertake complex treatments over a longer period;
 - ▶ patient's norms and values/cultural acceptance;
 - ▶ Initial costs and long-term maintenance costs.
- Identify patient perspectives and preferences
- Ensure the patient understands the different implications of the treatment chosen, i.e. duration, limited lifespan of all restorations and protheses and personal involvement of each patient in terms of oral hygiene and follow up.
- Identify the main risks and main benefits of the different technologies available.
- Checklist before undertaking definitive care:
 - ▶ Assess patient's overall health condition;
 - ▶ Assess patient ownership;
 - ▶ Ensure stability of primary oral disease;
 - ▶ Assess compliance or cooperation to review risk;
 - ▶ Review definitive care plan (rehabilitation and long-term maintenance);
 - ▶ Secure patient's informed consent.
- If you have chosen to share the care between a generalist/primary care dentist and a specialist clinician, stabilization of disease and ongoing maintenance will most likely be managed by the generalist/primary care dentist.

Patient-dentist communication → An interactive patient-dentist communication will help your patients understand what is best for them and choose the most appropriate treatment plan.

Long-term care → Planning systematic review appointments after treatment will help shape a tailor-made treatment and care plan for my patients.

| TREATMENT | INDICATIONS | PATIENT PERSPECTIVE | MAIN BENEFITS | MAIN RISKS | AVERAGE LIFESPAN | MANAGING FAILURE: WHAT'S NEXT? | |
|--|---|--|--|--|--|--|---|
| NO RESTORATION <i>Accept the missing tooth and maintain residual dentition</i> | <ul style="list-style-type: none"> No or minimal functional limitation. Patient not motivated to replace missing teeth. | <ul style="list-style-type: none"> The probability a patient will accept a missing tooth will partly depend on where it is located. | <ul style="list-style-type: none"> Simplifies maintenance, reduced biological price of prosthetic treatment. | <ul style="list-style-type: none"> May compromise future rehabilitation if further teeth are lost, leading to functional limitation. Tipping of teeth adjacent to space, over-eruption of opposing tooth: these need to be monitored and may lead to compromised oral function | | <ul style="list-style-type: none"> May need to restore space if there is significant tooth movement, or further tooth loss. | |
| ORTHODONTICS | <ul style="list-style-type: none"> Desired aesthetic and functional outcome can be achieved by tooth movement only. Alignment of teeth to facilitate fixed prosthodontic rehabilitation. Closure of spaces and alignment of teeth that may facilitate other care pathways. | <ul style="list-style-type: none"> Extended care pathway, particularly in older adults. Extended course of orthodontic care prior to prosthetic rehabilitation can take 6 months to 2 years (depending on the malalignment). Fixed appliances may be aesthetically or functionally unacceptable to the patient. | <ul style="list-style-type: none"> May achieve outcome without damaging natural teeth. May achieve clinical outcomes without operative intervention. May improve options for further care. May be able to use less destructive methods for reconstruction. | <ul style="list-style-type: none"> Plaque accumulation around the orthodontic appliance leading to caries and increased periodontal disease risk. Root resorption during orthodontic treatment, which reduces the ability of teeth to support their fixed prosthesis. Contra-indicated in the presence of active periodontal disease. Failure to move the teeth. | <ul style="list-style-type: none"> If orthodontics only, may require life-long retention/fixed retainers. | <ul style="list-style-type: none"> Revise plan of care if it fails. | |
| RESTORATION | <i>Conventional fixed partial denture (bridge)</i> | <ul style="list-style-type: none"> Can use fixed-fixed, fixed-removable or cantilever designs. Can extend into space but limited number of cantilevered units practical without increasing risk of failure. Cantilevers good for replacing single units if supporting teeth are sound | <ul style="list-style-type: none"> Improved Quality-of-Life (QoL) Potentially improves oral function and patient satisfaction for patients who report negative impacts following partial tooth loss | <ul style="list-style-type: none"> Fixed in place. Occlusal protection of restored abutment teeth when there is substantial loss of tissue structure. Can have good aesthetics when bone resorption in pontic area is limited. | <ul style="list-style-type: none"> Destruction of tooth tissue with extent of destruction exacerbated by different materials options (all-ceramic is worse than metal-ceramic). Loss of vitality as a consequence of preparation / repeated trauma through life, particularly for a previously restored tooth. Restored teeth at greater disease risk than non-restored embrasure spaces More difficult to clean, especially beneath pontics Risk of rotational failure with linked abutments and unfavourable leverage forces from pontics Plaque accumulation around abutments, leading to gingival inflammation and/or caries at margin. Higher risk of caries due to difficulty in maintenance Mechanical failure of abutment tooth if it has been endodontically treated. Fracture of the veneering material. | <ul style="list-style-type: none"> 98% 5-year survival rate with metal-ceramic restorations; 93% 5-year survival rate for all-ceramic restorations Natural teeth change colour with age; they tend to become more opaque and yellow/brown in colour. Patients can perceive an aesthetic mismatch between ceramic restorations and natural teeth with time because of change in appearance of their natural teeth. Should this occur, you should consider attempting to whiten the natural teeth to make them closer to their original colour rather than remaking the crowns. | <ul style="list-style-type: none"> Improve oral hygiene. Removal of marginal caries and seal with adhesive restorative material. Replace bridge if abutment tooth is lost, design driven by length of span and patient preference. Attempt repair of fractured porcelain or worn resin veneering material with adhesive material or adjust sharp edges; may need replacement if repair fails. |
| | <i>Resin-bonded fixed partial denture (bridge)</i> | <ul style="list-style-type: none"> Can only be used predictably on relatively short spans. Evidence suggests greater success with 2-unit cantilever compared with 3-unit fixed-fixed designs. Anterior bridges have better survival rate than posteriors. | <ul style="list-style-type: none"> Improved QoL | <ul style="list-style-type: none"> Minimal or no tooth preparation, less destructive than conventional preparations. | <ul style="list-style-type: none"> May compromise future rehabilitation if further teeth are lost, leading to functional limitation. Biological price of tooth preparation for prostheses. Increased maintenance requirement for patient. Plaque accumulation around abutments, leading to gingival inflammation and/or caries at margin. Partial decementation, which can lead to caries on the underlying abutment. Decementation, particularly posterior bridges, leading to loss of bridge. Chipping of veneer porcelain from frameworks. Greying of anterior abutment teeth with metal retainer wings. | <ul style="list-style-type: none"> 91.4% 5-year survival rate; 82.9% 10-year survival rate Natural teeth change colour with age; they tend to become more opaque and yellow/brown in colour. Patients can perceive an aesthetic mismatch between ceramic restorations and natural teeth with time because of change in appearance of their natural teeth. Should this occur, consider attempting to whiten the natural teeth to make them closer to their original colour rather than remaking the crowns. | <ul style="list-style-type: none"> Improve oral hygiene. Removal of marginal caries and seal with adhesive restorative material for early caries. For partial decementation, remove the overlying wing and treat underlying caries if detected; leave remaining structure as a cantilevered bridge. For decementation, attempt replacement, need to ensure removal of adhesive from both the bridge wings and the tooth surface. For repeated decementation, consider alternative replacement options such as implant retained crown/bridge or conventional bridge. |
| | <i>Removable partial denture (RPD)</i> | <ul style="list-style-type: none"> Good at replacing multiple missing teeth. Good at restoring defects in alveolar bone/gingivae if lost. Can be used to replace teeth in “free end saddle” situation readily. In case of further tooth loss, the prosthesis can sometimes be modified if design permits. Good for terminal dentition phase and planning. | <ul style="list-style-type: none"> Often not perceived as a ‘denture’ and better accepted as a ‘partial’ or a ‘removable bridge’. High degree of non-compliance with use, in particular when replacing posterior teeth. Improvement of problems related to smiling and eating. | <ul style="list-style-type: none"> Can be low cost. Simple to manufacture and use. Can be made (especially when made from acrylic) in a low-tech environment. | <ul style="list-style-type: none"> Increased disease risk for both caries and periodontal disease. Further tooth loss, potentially compromising the function and comfort of the prosthesis. Loss of denture teeth from the prosthesis. Mechanical failure. Removable and may not be stable depending on quantity of support/retention available. Not well-liked / tolerated, particularly with distal extension prostheses. Poor compliance with wearing and/or with home care. | <ul style="list-style-type: none"> (Caveat – removable prostheses more likely to be provided to patients with higher risk of tooth loss) Abutment teeth for removable partial dentures are most vulnerable to disease and increased risk of further tooth loss. Survival influenced by standard of oral hygiene and frequency of maintenance programme; level of periodontal support and endodontic status of abutment teeth; 5-year survival rate of abutment teeth ranges from 70-83%. Survival rate for RPDs are likely to be affected by selection bias, in that people at the greatest risk of further tooth loss are more likely to be offered an RPD. | <ul style="list-style-type: none"> Reinforce oral hygiene. Replace missing tooth oor modify the denture to maintain retention; if not possible, then remake denture. Modification of the prosthesis or replacement with new prosthesis may be necessary if more natural teeth are lost in the future. |
| | <i>Dental Implant(s) and restoration</i> | <ul style="list-style-type: none"> Can be used anywhere there is bone or when bone augmentation is possible. Can be used to support/retain a very wide range of prostheses. | <ul style="list-style-type: none"> Improved QoL. Reluctance to pursue a surgical procedure due to self reported frailty in elderly patients. Lay people tend to have high expectations regarding the capacity of implants to restore appearance, function and QoL to normal levels. They overestimate function and longevity and underestimate the expertise needed to carry out the clinical procedures. | <ul style="list-style-type: none"> Predictable in most people. High level of patient satisfaction. Can get good aesthetics if planned and executed properly. | <ul style="list-style-type: none"> Peri-implant disease (especially in the presence of periodontal disease elsewhere in the mouth). Mechanical failure of the implant or connecting mechanisms. Prosthetic failure. May need to create/augment bone with increasing complexity of procedures. Reduced survival rate in smokers. Better survival rates in mandible than maxilla. Use in other risk groups: <ul style="list-style-type: none"> Medication-related Osteonecrosis of the Jaw (MRONJ) People with diabetes, particularly poorly controlled Damage to structures in bone (nerves). Fracture of veneer material on superstructure when porcelain is used over metal. Screw loosening of screw-retained prostheses or loss of retention of cemented restorations Implant fracture, screw fracture, etc. As a broad generalization, screw-retained prostheses are easier to maintain and more adaptable than cement-retained prostheses | <ul style="list-style-type: none"> (Caveat – may depend on the treatment protocols. Delayed loading has a slightly better long-term survival than immediate loading protocols; survival in non-grafted bone slightly better than grafted bone. Will also be influenced by implant surface (machined/roughened) and materials used to construct prosthesis). Survival of implants 96% after 5 years, 93% after 10 years; survival of restorations 95% after 5 years and 80% after 10 years of function. Natural teeth change colour with age; they tend to become more opaque and yellow/brown in colour. Patients can perceive an aesthetic mismatch between ceramic restorations and natural teeth with time because of change in appearance of their natural teeth. Should this occur, consider attempting to whiten the natural teeth to make them closer to their original colour rather than remaking the crowns. | <ul style="list-style-type: none"> Treatment of peri-implantitis as it occurs. Repair and/or replacement of restorations as they fail. Modification of the type of prosthesis, for example converting a fixed prosthesis to an implant-supported overdenture, may make the delivery of personal oral health care easier. Removal of implants may be necessary in serious cases, and other options may have to be considered. |
| | <i>Combined options: implant-supported RPD; tooth-supported overdenture, etc.</i> | <ul style="list-style-type: none"> Long spans, reduced bone volume, lower costs when compared to fixed prostheses. Varies according to individual situations. | <ul style="list-style-type: none"> Improved QoL. Need to explain to patients the rationale and advantages of using a combined approach. | <ul style="list-style-type: none"> Adequate retention for a removable prosthesis; retaining natural teeth to support an overdenture preserves proprioception. | <ul style="list-style-type: none"> Tooth supported overdentures have a high disease risk, need a high standard of oral hygiene to preserve abutments. Increased caries risk on abutment teeth. Further tooth loss, potentially compromising the function and comfort of the prosthesis. Development of peri-implantitis around the implants, increased risk in patients with periodontal disease. Mechanical failure of the implant or connecting mechanisms. Loss of denture teeth from the prosthesis. Prosthetic failure. | <ul style="list-style-type: none"> Evidence for survival in tooth-supported overdentures is very limited. | <ul style="list-style-type: none"> Reinforce oral hygiene. Replace missing tooth or modify the denture to maintain retention; if not possible, then remake denture. Modification of the prosthesis or replacement with new prosthesis may be necessary if more natural teeth are lost in the future. Treatment of peri-implantitis as it occurs. Repair and/or replacement of restorations as they fail. Modification of the type of prosthesis, for example converting a fixed prosthesis to an implant-supported overdenture, may make the delivery of personal oral health care easier. Removal of implants may be necessary in serious cases, and other options may have to be considered. |
| | NO RESTORATION <i>Controlled progression to edentulism</i> | <ul style="list-style-type: none"> Unstable, advanced disease, not responding to treatment, or poor compliance by patient, poor prognosis for remaining natural dentition. | <ul style="list-style-type: none"> Potentially improves oral function and patient satisfaction for patients who report negative impacts following partial tooth loss. | <ul style="list-style-type: none"> Reduction of pathogens in the oral cavity with potential positive health impact. Improves oral comfort. Potential to improve chewing function. | <ul style="list-style-type: none"> Patient fails to adapt to total tooth loss. | | <ul style="list-style-type: none"> Consider implant-supported prostheses (fixed or removable), particularly in younger, middle-aged adults, to reduce the impact of post-extraction alveolar bone loss. |
| Restoration to shortened dental arch (SDA) | <ul style="list-style-type: none"> Some functional limitation, aesthetic impact of missing anterior teeth. | <ul style="list-style-type: none"> Randomized Controlled Trials (RCTs) indicate that restoration to SDA is equally acceptable to replacement of missing teeth with RPD. | <ul style="list-style-type: none"> Improves oral function to an acceptable level. Simplifies maintenance, reduced biological price of prosthetic treatment. | <ul style="list-style-type: none"> May compromise future rehabilitation if further teeth are lost leading to functional limitation. | | | |
| Restoration to complete dentition | <ul style="list-style-type: none"> Significant functional limitation, aesthetic impact of missing anterior teeth. | <ul style="list-style-type: none"> Potentially improves oral function and patient satisfaction for patients reporting negative impacts following partial tooth loss. | <ul style="list-style-type: none"> Improves oral function to an optimal level. | <ul style="list-style-type: none"> Biological price of tooth preparation for prostheses. Increased maintenance requirement for patient. | | | |



Patient education

As a dentist, you understand that a thorough dialogue with your patients will ensure they have sufficient information to properly maintain their restorations and take ownership of the long-term care and maintenance that is needed. Your discussion should focus on risk awareness, treatment lifespan, managing failure together, and oral hygiene instructions.

Well-informed patients will be better equipped to monitor risks, take ownership of their treatment, not feel cheated, understand that there are no “forever solutions”, and call on their dentist in case of need. Depending on the type of treatment performed, specific oral hygiene routines may apply. These routines have been outlined below to support your communication with your patients.

- Reinforce oral hygiene and dietary advice to reflect the caries and periodontal risk status of the individual for their remaining natural teeth. Review oral hygiene on specified interval of recall.
- Daily toothbrushing with a toothpaste containing at least 1,100 ppm fluoride for a patient with low caries risk. Consider 5,000 ppm fluoride toothpaste daily and professional application of fluoride gels or varnish or the use of silver diamine fluoride or chlorhexidine varnish every three months if the patient has a high caries risk status, has a history of recurrent root caries, or has a tooth-supported overdenture.
- Interdental cleaning aids such as dental floss or brushes.
- Thorough cleaning of the denture outside of the mouth with a soft-bristled toothbrush and recommend immersion in a suitable denture cleaner. Metal-based dentures should not be immersed in cleaners containing hypochlorite solutions.
- Ensure an adequate understanding of the need to maintain hygiene of the prosthesis and oral soft tissues. Advise the patient to consider removing the denture overnight and soak it in a denture cleaner.
- Ensure the patient understands the need for routine recall for oral health screenings, even when edentulous.
- Annual recall for low-risk patients, 3-6 month recall for moderate- to high-risk patients. Recall is every 3-6 months due to a higher risk of tooth loss in patients wearing removable partial dentures.
- Monthly follow-up appointments for prosthesis adjustment.

Support

Sponsorship for the development of these guidelines was provided by GlaxoSmithKline Consumer Healthcare to the FDI without exercising editorial control, apart from ensuring compliance with legal and regulatory considerations/requirements.



Recognition

Content developed by Partially Dentate Patients project experts (P.F. Allen, W. Cheung and A. Walls).

Find out more

Quickly access the project page by scanning the following QR code using your mobile phone camera.

